

Topic: CV exam - RBBB (Exam)

Subject: Medicine

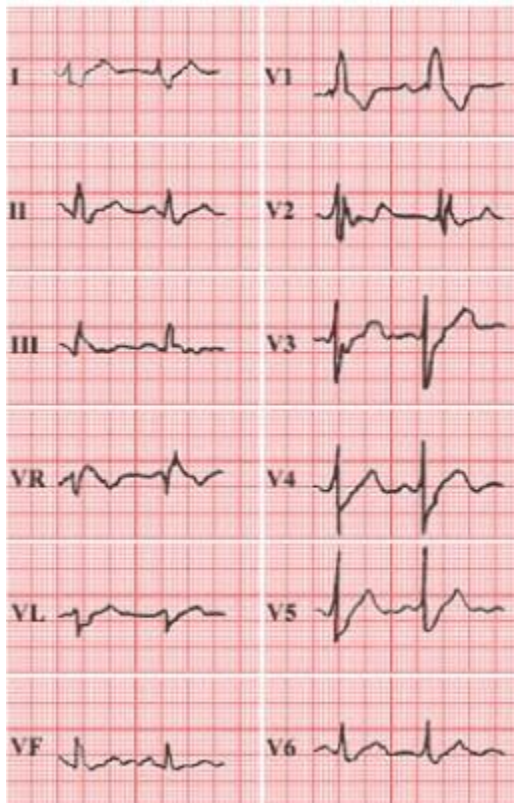
ID: 213

**COUPLET STATION CASE ONE - PHYSICAL EXAMINATION STATION
WHAT THE CANDIDATE READS**

CANDIDATE'S INSTRUCTIONS

A male aged 45 asked for "a check up, a cardiograph and tests for blood fats". He said that he was quite well. There was no significant past or family history. No abnormality was found on physical examination. He returns to discuss the results of his check up. The blood lipids were normal.

His ECG is below



In the next 5 minutes, interpret the ECG and perform a relevant and focused physical examination.

At the next station, you will be asked to answer questions about this patient.

WHAT THE EXAMINER COMPLETES

EXAMINER'S CHECKLIST

Fill in the bubble for each item completed satisfactorily.

- 1. Candidate advises that patient has RBBB.
- 2. Explains to the patient that this is likely a minor abnormality which is common in healthy people. It occurs when there is interruption of the passage of the impulse through either bundle. This interruption may be permanent, transient or intermittent. It may be partial or complete.
- 3. Advises patient to maintain a healthy lifestyle and to visit if he has any problems.
- 4. Does a physical exam of the cardiovascular system:
 - Examine finger nails and palms for evidence of bacterial endocarditis.
 - Examine eyes, mouth and tongue for evidence of cyanosis.
 - Inspect neck for engorged jugular veins.
 - Check pulses in all major arteries.
 - Check for collapsing pulse in the brachial artery while lifting the arm.
 - Palpate chest to locate the apex and to detect left sternal hump.
 - Auscultate heart at the 4 major points while palpating the carotid artery.
 - Auscultate apex while the patient leans to the left.
 - Examine abdomen for hepatjugular reflex and for shifting dullness.
 - Examine back for basilar rales and for sacral edema.
 - Examine legs for pitting edema.

| | | |
|---|-------------------------------------|--|
| <p><i>Did the candidate respond satisfactorily to the needs/problem(s) presented by this patient?</i></p> | | <p>If UNSATISFACTORY, please specify why:</p> <p><i>(For items 4-6, please explain below)</i></p> |
| <p><u>SATISFACTORY</u></p> | <p><u>UNSATISFACTORY</u></p> | <p>1 Inadequate medical knowledge and/or provided misinformation</p> |
| <p>A Borderline</p> | <p>A Borderline</p> | <p>2 Could not focus in on the patient's problem</p> |
| <p>B Good</p> | <p>B Poor</p> | <p>3 Demonstrated poor communication and/or interpersonal skills</p> |
| <p>C Excellent</p> | <p>C Excellent</p> | <p>4 Actions taken may harm this patient</p> |
| | | <p>5 Actions taken may be imminently dangerous to this patient</p> |
| | | <p>6 Other</p> |
| <p><i>Do you have concerns regarding this candidate's ethical and/or professional behavior?</i></p> | | |
| <p>? Yes (please specify) ? No</p> | | |

WHAT THE CANDIDATE RECEIVES

POST-ENCOUNTER PROBE

Q1. *What is Rate/min and interpret abnormalities?*

Q2. *What are the most common causes?*

Q3. *Which is more likely to be an indicator of serious underlying disease, LBBB or RBBB?*

WHAT THE PEP MARKER RECEIVES

ANSWER KEY

Q1. *What is Rate/min and interpret abnormalities?*

| | <u>SCORE</u> |
|---|--------------|
| A1. Rate/min: 80-100 | 1 |
| Duration prolonged to 0.16 secs in leads 1, V5 and V6 | 1 |
| Normal R waves and notched S waves in V1 and V2 | 1 |
| The R wave is "M" shaped | 1 |
| In leads 1, V1, V5 and V6, T wave is in the opposite direction to the main QRS. | 1 |
| Rhythm strips (long strips) are required to recognise the presence of arrhythmias and to define the ECG diagnosis | 1 |
| Maximum | 4 |

Q2. *What are the most common causes?*

| | <u>SCORE</u> |
|----------------------------|--------------|
| A2. Normal variant | 1 |
| Ischaemic heart disease | 1 |
| Hypertensive heart disease | 1 |
| Cardiomyopathy | 1 |
| Maximum | 4 |

Q3. *Which is more likely to be an indicator of serious underlying disease, LBBB or RBBB?*

| | <u>SCORE</u> |
|----------------|--------------|
| A3. LBBB | 2 |
| Maximum | 2 |